

CASE REPORT

Effectiveness of Alphachymotrypsin on The Treatment of Severe Paralysis Due To Bungarus Multicinctus Snakebite

LE QUANG THUAN¹, DUE PHAM^{2,*}, BE HONG THU²

¹Instructor, Poison Control Center, Bach Mai Hospital, Vietnam

²Associate Professor, Poison Control Center, Bach Mai Hospital, Vietnam

Abstract

Background: In Vietnam, there are two main species of Bungarus: *Bungarus multicinctus* and *Bungarus candidus*. Trypsin is a serine protease digestive enzyme that has demonstrated efficacy in some of *Elapidae* envenomations. After their experiments with dogs and mice, Hsiung Yu-Liang et al. concluded the local injection of trypsin can be used in clinical practice as a new and effective therapy for snakebite. We report a case of successful application of alphachymotrypsin, a related enzyme, in the treatment of severe paralysis due to *B. multicinctus* snakebite.

Case presentation: A 38-year-old man was bitten on his left hand by *B. multicinctus*. Two hours after the bite, the patient developed a sore throat, diffuse myalgia, and progressive paralysis. Since antivenom was not available, we decided to administer alphachymotrypsin after the risks and benefits were carefully discussed. A dose of 5000 IU alphachymotrypsin was administered by the IM route at 24 and 31 hours after bite. At the time of the first dose of alphachymotrypsin, muscle power was 0/5. The muscle power improved rapidly, from 0/5 (24 hours) to 2/5 (at 44 hours). After that, additional doses of 10.000 IU of alphachymotrypsin were administered at 45, 55, 69, 75, 94 and 100 hour after the bite; the muscle power increased gradually then to 3/5 (66 hours), 4/5 (75 hours), and 5/5 (97 hours).

Discussion: The severity of the patient can be estimated through some factors as following: the heavier and longer the snake, the more severe the threat, time from bite to symptoms: the sooner the more severe, the level of paralysis, and the level of hyponatremia. According to these signs, the patient was classified under the severe group because the snake was long and heavy (1.5 m and 300 gr), symptoms appeared right after 2 hours after the bite, and level of paralysis was 0/5 17 hours after the bite. The mild hyponatremia could be related to either a minor *B. multicinctus* envenomation, which is unlikely given the severity of the other clinical findings, or the effectiveness of *alphachymotrypsin*. This hypothesis requires further investigation, both mechanistically and clinically.

Conclusion: The use of alphachymotrypsin was associated with a shortening of the need for mechanical ventilation, length of ICU stay, and a reduced extent of hyponatremia in a patient with severe *B. multicinctus* envenomation.

Keywords: Alphachymotrypsin; Bungarus Multicinctus; Snakebite

How to cite this article: Quang Le T, Pham D, Hong Be T. Effectiveness of Alphachymotrypsin on The Treatment of Severe Paralysis Due To Bungarus Multicinctus Snakebite. *Asia Pac J Med Toxicol* 2018;7:24-7.

INTRODUCTION

Treatment for the bites by the many-banded krait (*Bungarus multicinctus*) is common at the Poison Control Center at Bach Mai Hospital (BMPCC). According to the BMPCC information unit, in 5 years (2010-2014) they accounted for 208 of the total of 1342 (15.5%) snakebite cases over that time period, with an annual average of 41.6 cases (17-61).

In Vietnam, there are two main species of Bungarus: *Bungarus multicinctus* (Northern Vietnam only) and *Bungarus candidus* (Malayan or blue krait, mainly in Southern Vietnam) (1, 2). The most consequential effect of envenomation, paralysis, typically appears about 3 hours (0.5-24 hours) following *B. multicinctus* bite. The clinical effects progress over time to jaw weakness (90%), pharyngeal pain (83%), palatal palsy (90%), neck muscle

paralysis (85%), limb paralysis (85%) and paralysis of the respiratory muscles (87%). Local effects are very mild, and there is typically no pain or swelling, despite the presence of two fang marks at the bite site (3). Hyponatremia, due to urine loss of sodium, is common (79%), and appears between 2 to 10 days after the bite, being most severe on day 2-4 (minimum 104 mmol/L) with average 128.4 ± 2.81 mEq/L, and could last up to 20 days (4, 2). Respiratory paralysis requiring mechanical ventilation, lasting for a mean of 8 days, is associated with complications such as hospital acquired pneumonia and pneumothorax, and carries a hospital mortality of up to 7% (3).

Antivenom administration is the mainstay of therapy in the majority of medically significant cases of envenoming. Such specific therapy may dramatically reduce the consequences of the envenomation (5, 6-8). Supportive care, including mechanical ventilation and 2% sodium infusion, is an

*Correspondence to: Dr. Due Pham; MD. Associate Professor, Poison Control Center, Bach Mai Hospital, Vietnam
Tel: +84 913 00 44 66, Email: phamduehanoi@gmail.com
Received 08 February 2018; Accepted 12 March 2018

important part of the management of *Bungarus multicinctus* snakebite, especially for situations in which no antivenom is available (4).

An antivenom for *B. multicinctus* demonstrated impressive effectiveness by shortening mechanical ventilation time from 8.6 ± 8.1 to 2.3 ± 2.5 days, decreasing the number of patients who developed ventilator-associated pneumonia, and shortening the length of ICU stay from 11.6 ± 9.7 to 6.1 ± 3.2 days. Rapid initiation of antivenom therapy is associated with improved outcomes (5).

However, *Bungarus* antivenom is not immediately available. As a horse-derived product, it carries a high risk of potential adverse events such as anaphylaxis, anaphylactoid reaction and delayed serum sickness. These have been reported to occur in 18% of the receiving North American Coral Snake Antivenin, a related antivenom (9).

Trypsin is a serine protease digestive enzyme that has demonstrated efficacy in some of *Elapidae* envenomations. After their experiments with dogs and mice, Hsiung Yu-Liang et al. concluded the local injection of trypsin can be

used in clinical practice as a new and effective therapy for snakebite (10). Furthermore, Parker-Cote et al. concluded that in an animal model local injection of trypsin at the site of envenomation decreased the toxicity of eastern coral snake venom and increased survival significantly (9, 11).

We report a case of successful application of alphachymotrypsin, a related enzyme, in the treatment of severe paralysis due to *B. multicinctus* snakebite. There are no previous reports about the use of trypsin or alphachymotrypsin in the treatment of patients with *B. multicinctus* snakebite.

CASE PRESENTATION

A 38-year-old man was bitten on his left hand by *B. multicinctus* (This kind of species was recognized by the patient after successful treatment and epidemic distribution of the snake) (1-3, 5). Two hours after the bite, the patient developed a sore throat, diffuse myalgia, and progressive paralysis. He was transferred to Thai Binh provincial hospital, where he required endotracheal intubation due to complete

Table 1. Evolution of clinical and laboratory tests

Day of treatment	1	2	3	3	4	4	4	5	6
Glasgow	15	15	15	15	15	15	15	15	15
Pulse (BPM)	110	107	101		105	96		90	
Sys. BP	170	170	150		160			140	130
Dia. BP	80	90	80		70			80	80
T max	37.3	37.7	37.5		37.8			37.3	37
Total urine 24h	1500	750	1300		5400			4300	
Time take blood	5h	17	5	17	5	13	20	5	5
Glucose (mmol/L)	8.2		6			7.2		6.4	5.2
Ure (mmol/L)	3.4		4.4			3.0	3.4	3.7	4.4
Creatinin (micmol/L)	65		75			71	76	71	77
GOT (U/L)	23		62			30		43	44
GPT (U/L)	19		54			55		82	88
Sodium infusion/day (mEq)	308	324	154		244			154	
Sodium oral/day (mEq)		170	170		170				170
Na (mmol/L)	140	133	134	135	132	130	137	133	138
Ka (mmol/L)	4.1	2.8	3.1	3.50	4.50	3.0	3.9	3.7	4.1
Cl (mmol/L)	100	99	104	105	104	97	105	100	104
Na urine			216						
Ka urine			39.8						
Cl urine			195						
Protein (g/L)	77.9							70.9	
Albumin (g/L)	44.7							37.5	
Procalcitonin (ng/mL)	0.03		0.05					0.07	
RBC	5.3	4.9							5
Hb	165	152							154
WBC/N	24	13							12
PLTs	299	240							331

flaccid paralysis. He was at Bach Mai PCC 17 hours after the bite.

On admission to the referral hospital, the patient was awake, oriented with the following vital signs: BP, 140/90 mmHg; HR, 100 BPM; RR depended on ventilation; SpO₂ 95% on 35% oxygen. Two fang puncture marks like pins were noticed at finger III of his left hand, but there was no local swelling and other changes. Neurological examination showed he had totally bilateral ptosis, dilated pupil 5 mm, ophthalmoplegia, jaw paralysis with inability to open his mouth, severe limb paralysis and total paralysis.

Routine laboratory tests:

Whole blood count: RBC 5.27 T/L; Hb 165 g/L; PLT 299 G/L; WBC 24 (Neutrophils 95,4%).

Coagulation test: PT 100 %; INR 1; APTTs 26; APTTbc 0.86; Fibrinogen 2.661g/L; Ethanol test: negative; Von-Kaulla tesst > 60 phút.

Biochemistry test: Ure 3.4 mmol/L, Creatinine 65µmol/L; Glucose 8.2 mmol/L; GOT 23 U/L; GPT 19 U/L; CK 329 U/L; Na 140 mmol/L, K 4.09 mmol/L, Cl 99.9 mmol/L; Protein 77.9 g/L; Albumin 44,7 g/L; Procalcitonin 0.034 ng/mL.

Urine test: RBC 0 /µL; WBC 0; Protein 0 g/L.

Blood gas: pH 7.33; pCO₂ 35 mmHg, PO₂ 231 mmHg; HCO₃ 18.5 mmol/L (BE -7.4 mmol/L); Lactate 6.3 mmol/L (table 1).

Since antivenom was not available, we decided to administer alphachymotrypsin after the risks and benefits were carefully discussed. A dose of 5000 IU alphachymotrypsin was administered by the IM route at 24 and 31 hours after bite. At the time of the first dose of alphachymotrypsin, muscle power was 0/5. The muscle power improved rapidly, from 0/5 (24 hours) to 2/5 (at 44 hours). After that, additional doses of 10.000 IU of alphachymotrypsin were administered at 45, 55, 69, 75, 94 and 100 hour after the bite; the muscle power increased gradually then to 3/5 (66 hours), 4/5 (75 hours), and 5/5 (97 hours) (figure 1). The decision of pulling out the tracheal tube was at the 101th after the bite. The total mechanical ventilation time was 86 hours (~ 3.6 days). The total dose of alphachymotrypsin administered was 60.000 IU.

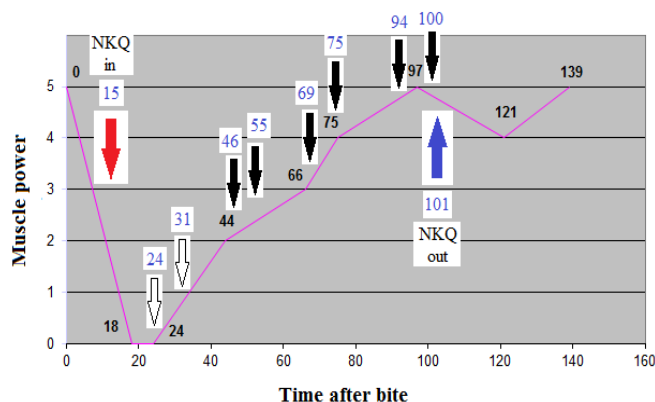


Figure 1. Evolution of muscle power condition and the use of alphachymotrypsin

(*Alphachymotrypsin:* Empty arrow: 5000 UI, thick arrow: 10.000 UI; *Muscle power scale:* Point 0: total paralysis, Point 1: movement of some of a muscle group, Point 2: muscle power weaker than contradiction power, Point 3: muscle power stronger than contradiction power, Point 4: muscle power well, Point 5: normal muscle power; NKQ = tracheal tube).

Comment: Total time of tracheal tube and mechanical ventilation was 86 hours (~3.6 days); total dose of alphachymotrypsin was 60.000 UI.

DISCUSSION

Diagnosis of *Bungarus* snakebite is simple if the patient sees and catches the snake. In case the snake has not been seen, diagnosis is usually due to triage: history of a bite, local symptom with two fang marks like pins, clinical symptoms with varying levels of paralysis even die by respiratory paralysis with dilated pupil, and laboratory test showed hyponatremia due to urine sodium loss.

The severity of the patient can be estimated through some factors as following: the heavier and longer the snake, the more severe the threat, time from bite to symptoms: the sooner the more severe, the level of paralysis, and the level of hyponatremia. According to these signs, the patient was classified under the severe group because the snake was long and heavy (1.5 m and 300 gr), symptoms appeared right after 2 hours after the bite, and level of paralysis was 0/5 17 hours after the bite. Based on our experience, he could be in mechanical ventilation from two weeks to months, or about 8 days according to Hung et al. in their study with a lot of complications and risk of mortality being 7% (3).

Prior research in pigs, dogs, and mice showed the beneficial effects on both clinical effects and mortality of trypsin for treatment of *Bungarus* envenomation (9-11).

Moreover, no side effects with a higher dose of alphatrypmochysin – 200 times of usual dose – were reported (12).

The effect of alphachymotrypsin rapidly helped muscle power improvement. The duration of mechanical ventilation in this patient was much shorter in comparison to the typical patient (8 days per Hung et al., and 14-30 days based on our experience) (3).

The hyponatremia in this case was not severe, although the urinary sodium concentration is high, especially in light of the falling serum sodium. The death resulted by severe hyponatremia being reported in a case report of *B. multicinctus* before could be in relation with cerebral edema (2).

The mild hyponatremia could be related to either a minor *B. multicinctus* envenomation, which is unlikely given the severity of the other clinical findings, or the effectiveness of *alphachymotrypsin*. This hypothesis requires further

CONCLUSION

The use of alphachymotrypsin was associated with a shortening of the need for mechanical ventilation, length of ICU stay, and a reduced extent of hyponatremia in a patient with severe *B. multicinctus* envenomation. In evaluating the effect of alphachymotrypsin in the treatment of *Bungarus*

snakebite both in mechanistic and clinical toxicology, more study should be carried out in the future.

ACKNOWLEDGEMENTS

The authors would like to thank Prof. Lewis S. Nelson, Director of Medical Toxicology Fellowship Training Program; Department of Emergency Medicine, New York University Langone Medical Center and Bellevue Hospital Center for his kind and patient edit for the manuscript.

Conflict of interest: None to be declared.

Funding and support: None.

REFERENCES

1. Kim Son N. Research on clinical features and treatment for some kind of elapidae-snakebite's patients in the North of Vietnam. Vietnam: Hanoi Medical University; 2008.
2. Höjer J, Tran Hung H, Warrell D. Life-threatening hyponatremia after krait bite envenoming - a new syndrome. *Clin Toxicol (Phila)* 2010;48:956-7.
3. Hung HT1, Höjer J, Du NT. Clinical features of 60 consecutive ICU-treated patients envenomed by Bungarus multicinctus. *Southeast Asian J Trop Med Public Health* 2009;40:518-24.
4. Due P. Characteristics of hyponatremia in some kind of elapidae-snakebite's patient. *Vietnam J Practice Med* 2011;786:134-7.
5. Ha TH, Höjer J, Trinh XK, Nguyen TD. A controlled Clinical Trial of A Novel Antivenom in Patients Envenomed by Bungarus multicinctus. *J Med Toxicol* 2010;6:393-7.
6. Dart RC, McNally J. Efficacy, safety, and use of snake antivenoms in the United States. *Ann Emerg Med* 2001;37:181-8.
7. White J. Envenoming and antivenom use in Australia. *Toxicon* 1988;36:1483-92.
8. Karlson-Stiber C, Salomonson H, Persson H. A nationwide study of Vipera berus bites during one year - epidemiology and mortality of 231 cases. *Clin Toxicol* 2006;44:25-30.
9. Parker-Cote JL, O'Rourke D, Brewer KL, Lertpiriyapong K, Girard J, Bush SP, et al. Efficacy of Trypsin in Treating Coral Snake Envenomation in the Porcine Model. *J Med Toxicol* 2015;11:430-2.
10. Yü-liang H, Ju-chin T, Yi-ti H, Tz'u-chüan L, Hsing-liang C, Ching-yen L. Experimental Studies on Curing Elapid Bite with Trypsin. *Sci Sin* 1975;18:396-405.
11. Parker-Cote JL, O'Rourke DP, Miller SN, Brewer KL, Rosenbaum MD, Meggs WJ. Trypsin and rosmarinic acid reduce the toxicity of Micrurus fulvius venom in mice. *Clin Toxicol (Phila)* 2014;52:118-20.
12. Ray PK. Use of 200 Times the Recommended Dose of Alphachymotrypsin without Complications. *Br J Ophthalmol* 1964;48:230-1.