

CASE REPORT

Substituted Urea Herbicide (*Diuron*) Induced *Haemolytic* Anemia: A Case of Unknown Complication in Humans

WEERASINGHAGE SUNETH WEERASINGHE^{1*}, INDIKA BANDARA GAWARAMMANA², ANURADHA COLAMBAGE³

¹Medical registrar, Teaching Hospital, Peradeniya, Sri Lanka

²Consultant Physician (Professorial Medical Unit, Teaching Hospital Peradeniya), Senior Lecturer in Clinical Toxicology Department of Medicine, Faculty of Medicine, University of Peradeniya, Sri Lanka.

³Consultant Physician (Acting), Teaching Hospital Peradeniya, Sri Lanka

Abstract

Background: Substituted urea herbicide is widely used in the agricultural industry and is accessible to most people around the globe. Accidental or deliberate poisoning is an anticipated complication of these agrochemical products.

Case presentation: We present a 15-year-old girl following deliberate self-ingestion of substituted urea herbicide (*Diuron*). She was diagnosed with *Diuron* induced methemoglobinemia and treated with intravenous methylene blue. Later she developed hemolytic anemia and needed 3 units of blood transfusions. Her haemolysis was thought to be due to methylene blue with concomitant Glucose-6-phosphate dehydrogenase (G6PD) deficiency as no other possible cause was found for haemolysis. But on follow-up visits, G6PD deficiency was excluded by the screening test and enzyme level assay.

Conclusion: Hemolytic anemia is a possible rare complication that should be anticipated in patients presented with a significant amount of substituted urea herbicide poisoning. Studies have found the possibility of reactive oxygen species accumulation in cells leading to oxidative damage. But we were unable to find any reported cases of haemolysis in humans. We postulate that the inhibition of NADPH production like G6PD deficiency may be the key mechanism that causes haemolysis in humans by creating an acquired G6PD deficiency status in red blood cells. However, further studies are needed to identify the exact mechanism of hemolysis in humans.

Keywords: *Diuron*; *Haemolytic* Anemia; G6PD Deficiency; Methemoglobinemia; Substituted Urea Herbicide

How to cite this article: Weerasinghe WS, Gawarammana IB, Colambage A. Substituted urea herbicide (*Diuron*) induced haemolytic anemia: A case of unknown complication in humans. *Asia Pac J Med Toxicol* 2019;8(4):136-9.

INTRODUCTION

DCMU[4-(3,4-Dichlorophenyl)-1,1-dimethylurea] is a substituted urea compound first introduced as an herbicide in 1951 (1) and came to the market for commercial use in 1954. It is used to control a variety of annual-perennial broadleaf and grassy weeds. It has low toxicity to mammals and in humans, eye, throat and skin contact can irritate. Severe toxicity can cause nausea, vomiting, abdominal pain, diarrhea, methemoglobinemia and central nervous system depression causing respiratory failure and rarely haemolytic anemia (2). We report a patient who self-ingested a significant amount of DCMU, developed hemolytic anemia, needed blood transfusions and prolonged hospital stay.

CASE REPORT

A 15-year-old girl presented with deliberate self-ingestion of approximately 150ml of *Diuron* and was admitted to toxicology unit at teaching hospital Peradeniya in May 2018. She had felt dizzy and faintishness after ingestion and had

profuse vomiting. She became drowsy and found to have low capillary O₂ saturation(SPO₂) at the local hospital. She doesn't give a family history of haemolytic diseases or consanguinity. She was drowsy on admission and pulse rate – 86 bpm, blood pressure (BP) – 105/57 mmHg, respiratory rate (RR) – 24 bpm, lungs clear and other system examination was normal. Her SPO₂ was 88% on room air and ABG showed pH 7.36, PCO₂ – 26 mmHg, PO₂ – 112 mmHg, HCO₃ – 14.7 mmol/L, and base excess – (-10.7).

Gastric lavage and activated charcoal were given after admission. She was diagnosed with methemoglobinemia (methemoglobin level 40 %, estimated using the color chart method) and was treated with IV 1% methylene blue 5ml slow infusions till methemoglobin level dropped to 15% and supplementary oxygen was given and SPO₂ was improved to 98% on room air. She was kept under observation at the ICU. On 1st day of admission her Full blood count (FBC) showed white cell count (WBC) – 7600/uL, haemoglobin (Hb) – 12.6 g/dl, and Platelet (PLT) – 245 000/Ul. Her serum creatinine, liver enzyme, and serum electrolytes were normal. On the 6th

*Correspondence to: Weerasinghage Suneth Weerasinghe; MD. Medical registrar, Teaching Hospital, Peradeniya, Sri Lanka.
E-Mail: sunethws@hotmail.com, Tel: +94718142741
Received 19 July 2019; Accepted 15 November 2019

day, her haemoglobin dropped to 6.7 g/dl with macrocytosis (MCV – 106 fL) and reticulocyte count was 3.2%, LDH – 840 U/L, CPK 255 U/L, direct Coombs test negative, CRP, ESR and clotting profile was normal. Her blood picture was suggestive of haemolytic anemia with bite cells compatible with G6PD deficiency. She has transfused 3 units of packed red cells and eventually hemoglobin was stable. Non-contrast computed tomography (NCCT) brain showed no evidence of cerebral oedema, ECG and 2D ECHO cardiogram and ultrasound abdomen was normal. Exclusion of Glucose-6-phosphate dehydrogenase (G6PD) deficiency before starting methylene blue was not feasible due to the lack of facilities and acute haemolytic episode. Hence G6PD deficiency and methylene blue induced haemolysis was thought to be the most possible diagnosis and plan to investigate further to confirm.

She was discharged after 2 weeks and on follow-up visits, her haemoglobin level was and found to be static around 11 g/dl with no evidence of haemolysis in the repeat blood picture. Three months later Methaemoglobin reduction test (Brewer's test) was normal. Quantitative analysis of the G6PD activity was performed using G6PD activity quantitative spectrophotometric assay, which is a validated assay of G6PD deficiency (3). Her G6PD enzyme activity was 8 IU/g Hb (7 to 10 IU/g Hb) excluding G6PD deficiency. Genetic studies were not affordable for the patient.

DISCUSSION

Diuron is a substituted urea herbicide and it is widely used in the agricultural industry. Its mechanism of action is by inhibiting the photosynthesis of the plants (2). It inhibits the production of NADPH in plants by blocking electron transfer from primary acceptor (QA) to a secondary acceptor (QB) in the photosynthesis pathway causing increased oxidative stress and cell death (4) (Fig. 01).

According to the available literature, Diuron is less toxic

to humans but the effects, when ingested in large amount, are sparsely reported. The common clinical features of toxicity are nausea, vomiting, abdominal pain, diarrhea, methemoglobinemia and central nervous system depression causing respiratory failure (5). Animal studies are done to assess the toxicity showed the possibility of haemolytic anemia and secondary stimulation of erythropoietic activity (6, 7), though they were not reported in humans in the current literature.

Our patient presented with constitutional symptoms including vomiting, dizziness and developed methemoglobinemia. She was treated with IV methylene blue and developed haemolytic anemia. Micro angiopathic haemolytic anemia (MAHA), autoimmune haemolytic anemia, and sepsis causing disseminated intravascular haemolysis were less likely due to incompatible history, blood picture appearance, absence of other cytopenias and negative coombs test, normal inflammatory markers and clotting profile respectively.

Methemoglobinemia is a well-known toxic effect of diuron and in this patient, IV methylene blue is used to treat methemoglobinemia (5). In a G6PD deficient patient, it can induce haemolysis (8). G6PD deficiency is an X-linked recessive hereditary disorder and it is the most common enzyme defect affecting humans (9). Females are less affected than males due to its x link recessive inheritance, but a study done in Sri Lanka recruiting over 2,000 people from two main districts showed that the prevalence of G6PD deficiency distributed equally among males and females (10). Production of the NADPH is reduced in G6PD deficient red blood cells(RBC) making them vulnerable to oxidative stress induce haemolysis. (Fig. 02). Toxic chemicals, drugs, and infections were the commonest among many causes that can induce haemolysis (11). It is recommended to exclude G6PD deficiency prior to starting methylene blue but it may not be possible if the patient is having an acute haemolytic episode. Because in an acute haemolytic episode high reticulocyte

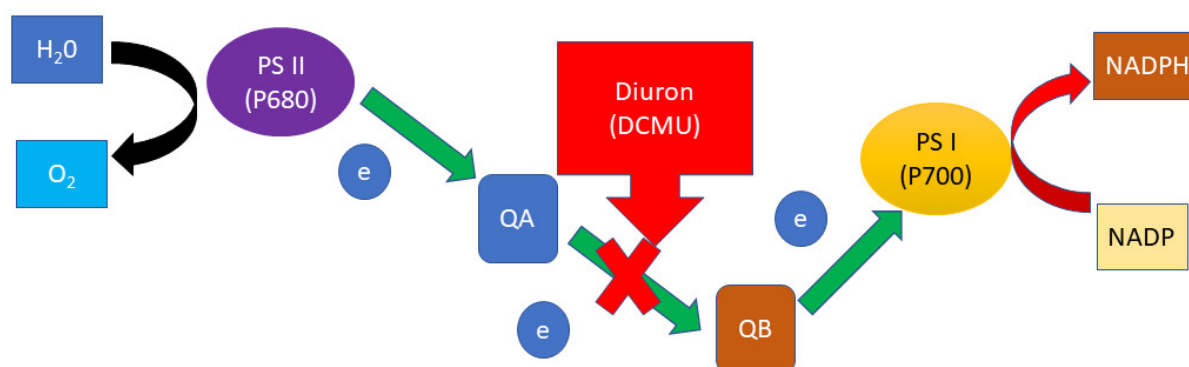


Figure 01. Diuron(DCMU) mechanism of action on photosynthetic electron flow. It blocks the electron transport and ultimately NADPH production.

H₂O – Water, O₂ – Oxygen, e- Electron, PS II(P680) - photosystem II, PS I (P700) – photosystem I, QA- primary acceptor, QB - secondary acceptor, NADP – Nicotinamide Adenine Dinucleotide Phosphate, NADPH - Reduced nicotinamide adenine dinucleotide phosphate

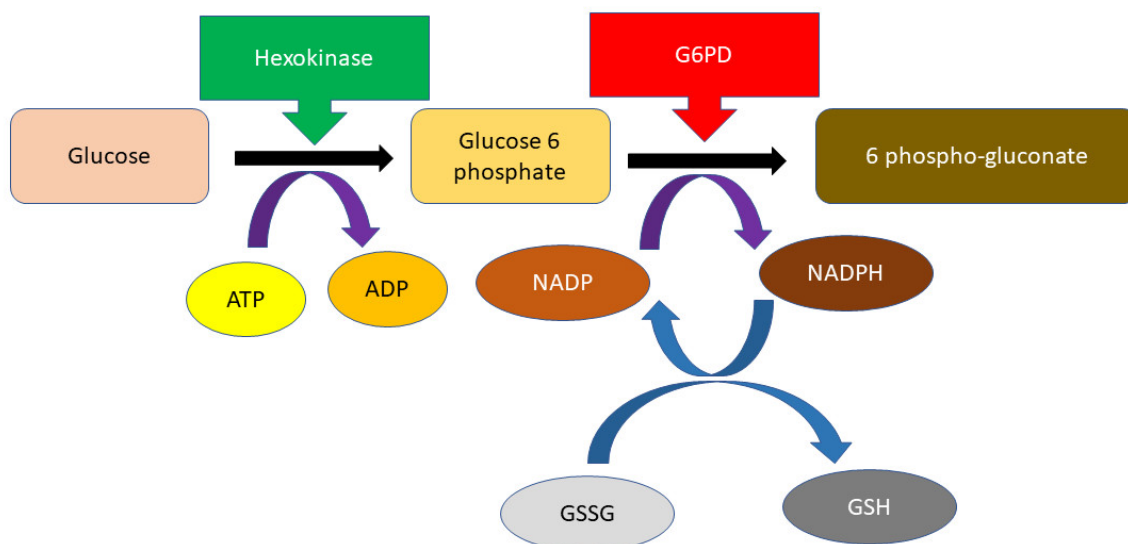


Figure 02. The pentose phosphate pathway of a human red blood cell. G6PD convert NADP+ to NADPH (reduced form) (G6PD : glucose-6-phosphate dehydrogenase; ATP : adenosine triphosphate; ADP : adenosine diphosphate; NADP+ : nicotinamide adenine dinucleotide phosphate [oxidized form]; NADPH : reduced NADP; GSSG : oxidized glutathione; GSH : reduced glutathione.)

count can give a false negative result (3, 12). On follow-up visits, she was screened for G6PD deficiency. The negative Brewer's test, which is a reliable screening for G6PD deficiency for decades (13, 14) had proved the haemolysis is unlikely to be due to G6PD deficiency but is most probably due to the Diuron. Normal G6PD enzyme assay further confirmed the fact.

Haemolytic anemia mimicking G6PD deficiency is not reported in humans in the literature to our knowledge. Some researchers have found that the production of reactive oxygen species (ROS) was statistically significantly increased in human cells in a study done to find the toxicity of Diuron in human cancer cells (15). We can postulate that the inhibition of the production of NADPH in plants may be the key mechanism that causes haemolysis in humans as in G6PD deficiency. Diuron may create an acquired G6PD deficiency status, making the patient susceptible to hemolysis under oxidative stress caused by the Diuron itself and the treatment, methylene blue. Studies done using rats proved that diuron can cause haemolysis and enlarge spleen and iron accumulation of the spleen (6). Hence extravascular haemolysis is the other possibility. However, the exact mechanism of haemolysis in humans is still not identified and further studies are required to confirm the exact mechanism.

CONCLUSION

substituted urea herbicide is widely used in many countries. Toxicological effects and mechanisms of this compound in humans are yet to be discovered as evident by this case. It is advisable to anticipate haemolytic anemia as a direct toxic effect of substituted urea herbicide and more studies need to be conducted in this field.

Consent for publication

Written informed consent was obtained from the patient for publication of this case report.

ACKNOWLEDGMENTS

We acknowledge the patient and her family for giving us the consent for publication of this case report.

Conflict of interest: None to be declared.

Funding and support: None.

REFERENCES

1. Bucha HC, Todd CW. 3-(p-Chlorophenyl)-1,1-dimethylurea; a new herbicide. *Science* 1951;114:493-4.
2. Pfister K, Arntzen CJ. The Mode of Action of Photosystem II-Specific Inhibitors in Herbicide-Resistant Weed Biotypes. *Zeitschrift für Naturforsch C* 1979;34:996-1009.
3. Minucci A, Giardina B, Zuppi C, Capoluongo E. Glucose-6-phosphate dehydrogenase laboratory assay: How, when, and why? *IUBMB Life* 2009;61:27-34.
4. Jin Y, Chen S, Fan X, Song H, Li X, Xu J, et al. Diuron treatment reveals the different roles of two cyclic electron transfer pathways in photosystem II in *Arabidopsis thaliana*. *Pestic Biochem Physiol* 2017;137:15-20.
5. Diuron - National Library of Medicine HSDB Database [Internet]. [cited 2019 Mar 15]. Available from: <https://toxnet.nlm.nih.gov/cgi-bin/sis/search/a?dbs+hsdb:@term+@DOCNO+382>
6. Wang SW, Chu CY, Hsu JD, Wang CJ. Haemotoxic effect of phenylurea herbicides in rats: role of haemoglobin-adduct formation in splenic toxicity. *Food Chem Toxicol* 1993;31:285-95.
7. Domingues A, Grassi TF, Spinardi-Barbisan ALT, Barbisan LF. Developmental exposure to diuron causes splenotoxicity in male Sprague-Dawley rat pups. *J Environ Sci Heal Part B*

- 2012;47:420–6.
8. Sikka P, Bindra VK, Kapoor S, Jain V, Saxena KK. Blue cures blue but be cautious. *J Pharm Bioallied Sci* 2011;3:543–5.
 9. Frank JE. Diagnosis and management of G6PD deficiency. *Am Fam Physician* 2005;72:1277–82.
 10. Gunawardena S, Kapilnanda GMG, Samarakoon D, Maddevithana S, Wijesundera S, Goonaratne LV, et al. Prevalence of G6PD deficiency in selected populations from two previously high malaria endemic areas of Sri Lanka. *PLoS One* 2017;12:e0171208.
 11. Stanton RC. Glucose-6-phosphate dehydrogenase, NADPH, and cell survival. *IUBMB Life* 2012;64:362–9.
 12. Brewer GJ, Tarlov AR, Alving AS. Methaemoglobin reduction test: A new, simple, in vitro test for identifying primaquine-sensitivity. *Bull World Health Organ* 1960;22:633.
 13. Brewer GJ, Tarlov AR, Alving AS. Methaemoglobin Reduction Test * A New, Simple, in Vitro Test for Identifying Primaquine-Sensitivity. *Bull World Health Organ* 1960; 22: 633–40.
 14. Tizianello A, Pannacciulli I, Salvidio E. A Simplified Procedure for Brewer's Methemoglobin Reduction Test. *Acta Haematol* 1966;35:176–80.
 15. Huovinen M, Loikkanen J, Naarala J, Vähäkangas K. Toxicity of diuron in human cancer cells. *Toxicol In Vitro* 2015;29:1577-86.