

## CASE REPORT

# Rhabdomyolysis and Acute Respiratory Distress Syndrome Secondary to Multiple Wasp Stings

URAIORN SIRITEP<sup>1</sup>, KUSUMA CHINAROONCHAI<sup>2,\*</sup>

<sup>1</sup>Trauma Intensive Care Unit, Faculty of Medicine, Siriraj Hospital, Mahidol University, Bangkok, Thailand

<sup>2</sup>Division of Trauma Surgery, Department of Surgery, Faculty of Medicine, Siriraj Hospital, Mahidol University, Bangkok, Thailand

### Abstract

**Background:** Wasp stings usually cause local reactions such as itching, urticaria, angioedema and anaphylaxis. Life-threatening complications following multiple wasp stings are relatively rare and unexpected. However, rhabdomyolysis and acute respiratory distress syndrome following wasp stings are possible.

**Case presentation:** A middle-aged male worker was stung by a swarm of wasps all over his body while attacking a wasp's nest. He had pain, a swollen face and multiple blisters on his entire body. He initially received the standard treatment of intravenous antihistamine, anesthetic and steroid medications. On admission day, his urine output progressively decreased in volume and turned from clear to bloody in appearance, with the color tending to become progressively darker. A serum creatinine of 0.87 mg/dL and a creatinine phosphokinase of 1403 IU/L at admission confirmed rhabdomyolysis. The following day, his serum creatinine and creatinine phosphokinase rose, with the development of tachypnea with desaturation; a chest radiograph showed bilateral diffuse lung infiltration. He was subsequently diagnosed with acute respiratory distress syndrome (ARDS). A medical record review revealed that he had received only 1150 ml of intravenous fluid in 8 hours. Consequently, his ARDS may have been caused by an anaphylactic reaction to the wasp toxin rather than by a cardiogenic cause or volume overload. He was intubated and transferred from the general ward to the intensive care unit for close clinical monitoring. Mechanical ventilation and intravenous fluid support were given to achieve a minimum urine output of 1 ml/kg/hr. His clinical and biochemical pictures started to improve and normalize from the fourth day after ICU admission.

**Conclusions:** Wasp stings may cause both rhabdomyolysis and acute respiratory distress syndrome. Early detection and immediate supportive treatment is the mainstay to reduce morbidity and mortality in such cases.

**Keywords:** Acute Respiratory Distress Syndrome; Rhabdomyolysis; Wasp Sting

**How to cite this article:** Siritep U, Chinaroonchai K. Rhabdomyolysis and Acute Respiratory Distress Syndrome Secondary to Multiple Wasp Stings. *Asia Pac J Med Toxicol* 2017;6(4):132-5.

### INTRODUCTION

Wasp stings may result in a wide range of clinical presentations that can be life threatening if not diagnosed and treated in time. The manifestations vary from localized pain, erythema and edema at the site of the affected skin, to generalized urticarial rash, angioedema, dyspnea and hypotension, finally leading to anaphylaxis, which usually occurs within 10 minutes of the sting (1). Moreover, the stings can produce systemic reactions and organ dysfunction, including rhabdomyolysis, acute kidney injury (AKI), and acute respiratory distress syndrome (ARDS) (2, 3). Wasp stings are quite commonly observed in Thailand, though they are underreported; nevertheless, the presence of rhabdomyolysis or ARDS following a wasp sting is rare (3, 4). However, in Thailand, no cases of wasp sting victims having multiple organ dysfunction syndrome (MODS) have been reported. Here we present a case of a patient stung by multiple wasps who later developed rhabdomyolysis and ARDS.

### CASE PRESENTATION

A 50-year-old worker was stung by a swarm of wasps all over his body while raiding their nest to collect wasp larvae to cook. A few hours later, he had a painful, swollen face and multiple blisters. On coming to the hospital, he was admitted for observation of clinical signs of anaphylactic reaction. He was initially treated with intravenous (IV) anesthetic, antihistamine and steroid medications. He was an alcoholic with a history of epilepsy, but his other medical history was unremarkable.

At admission, he had no rash, laryngeal edema or other signs of severe anaphylaxis. He was conscious and afebrile, with a pulse of 84 beats/min, a respiratory rate of 20/min, and a blood pressure of 133/80 mmHg. Ten sting marks were noticeable on his trunk and all four limbs.

On the second day of admission, the patient developed hematuria and progressive oliguria. The initial investigations showed a normal blood count, with a hemoglobin (Hb) level of 11.3 g/dL. Serum creatinine (SCr) was 0.87 mg/dL, and

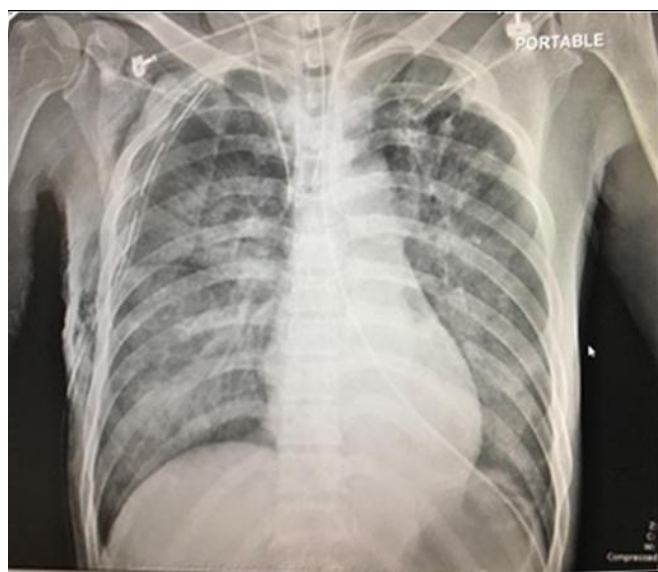\*Correspondence to: Dr. Kusuma Chinaroonchai, MD. Division of Trauma Surgery Office, 4<sup>th</sup> Floor Trauma Building, Siriraj Hospital. 2 Wanglang Road, Siriraj Subdistrict, Bangkoknoi District, 10700, Bangkok, Thailand.

Email: doctorchinaroonchai@hotmail.com, Tel: +662-419-7727-9, Fax: +662-419-7730

Received 14 October 2017, 24 November 2017

creatinine phosphokinase (CPK) was 1403 IU/L. A urine examination showed 2+ proteinuria, 3+ occult blood, and 20–30 RBCs/HP. However, the urine myoglobin level was not measured due to non-availability. Other investigations, including the coagulation profile and serum electrolytes, were normal. In a few hour after that, CPK increased (from 7850 to 10,595 IU/L within 6–8 hours), as did SCr (from 0.88 to 1.11 mg/dL).

On the basis of the patient's history, the clinical manifestations and the laboratory investigations, our diagnosis was rhabdomyolysis due to venomous wasp stings. An IV saline infusion was initiated and continued to keep the urine output at over 1 ml/kg/hr. Over the following 8 hours, having received 1150 ml of IV infusion, the patient produced only 325 ml of urine. The patient developed tachypnea with a respiratory rate of 32/min and with intercostal and subcostal retractions. Pulse oximetry revealed an oxygen saturation of 85% while breathing an oxygen concentration of 60%. His heart rate was 120/min, blood pressure was 140/90 mmHg, and heart sounds and JVP were normal. A central nervous system examination was normal except for irritability. A chest radiograph showed bilateral diffuse lung infiltrates (Figure 1).

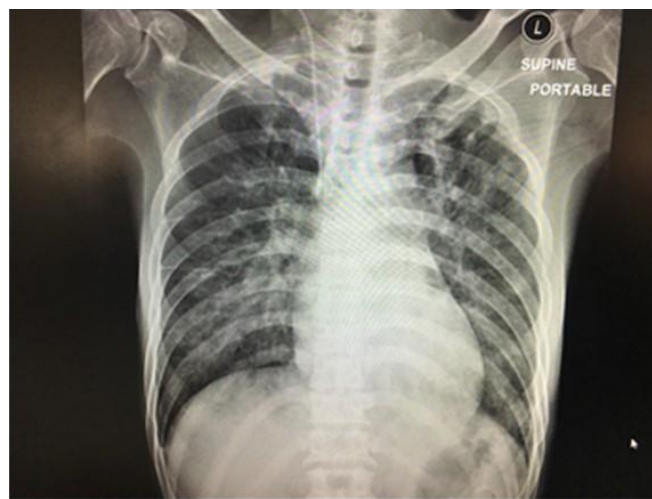

**Figure 1.** Bilateral patchy infiltration on chest radiography

Based on these findings, he was transferred to the intensive care unit (ICU) and was immediately intubated and ventilated. He required PEEP of 8 mmHg and 0.6 FiO<sub>2</sub> to maintain an oxygen saturation of > 95%. Arterial blood gas taken during ventilation showed a pH of 7.2, pO<sub>2</sub> of 110 mmHg, pCO<sub>2</sub> of 29 mmHg, and an O<sub>2</sub> saturation of 97%. The P/F ratio was 183. A central line was inserted for volume status evaluation. The IV saline infusion was continued to keep the urine output at over 1 ml/kg/hr. Metabolic acidosis was corrected with IV sodium bicarbonate; other supportive treatments were IV analgesic and sedative drugs. He received

lung-protective mechanical ventilation for 3 days before extubation.

From the fourth day after ICU admission, the clinical and biochemical pictures started to improve. Arterial blood gas taken while breathing a weaning oxygen concentration of 40% showed a pH of 7.48, pO<sub>2</sub> of 136 mmHg, pCO<sub>2</sub> of 33 mmHg, and an O<sub>2</sub> saturation of 98%. The chest radiography improved to nearly normal (Figure 2). The urine output gradually increased, with its color becoming lighter red and eventually clear and straw; both SCr and CPK also decreased slowly to normal (Figure 3).

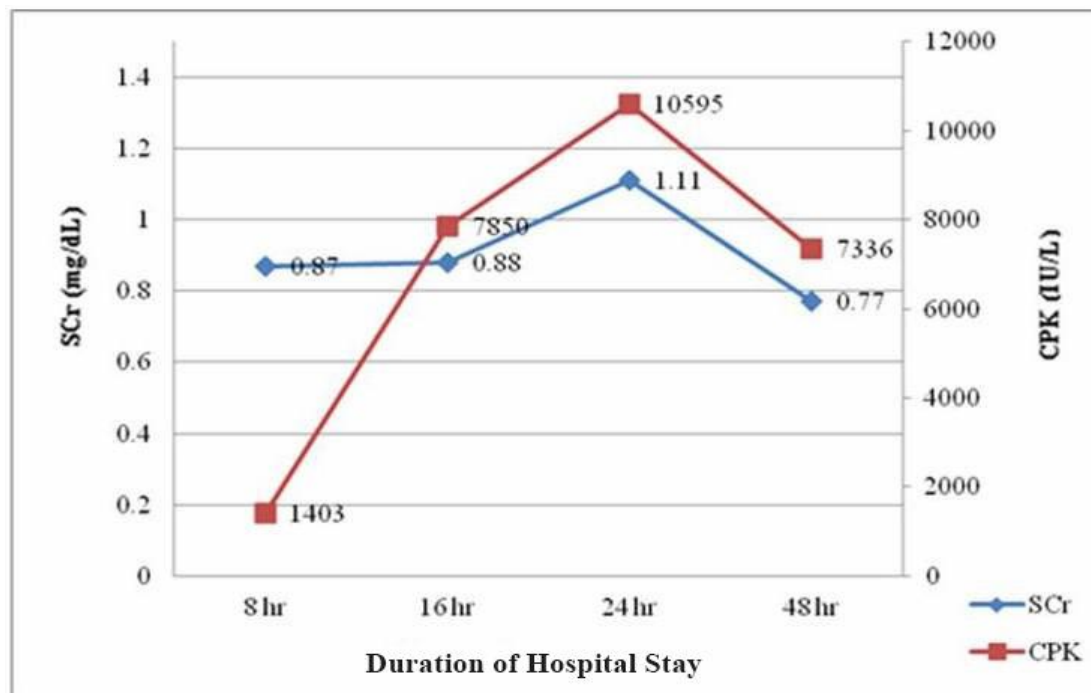


**Figure 2.** Nearly normal chest radiography after treatment

## DISCUSSION

When threatened or attacked, a wasp reacts by stinging in self-defense; if a wasp colony is disturbed, mass envenomation is likely to occur.<sup>5</sup> Wasp sting toxins include histamines, serotonin, phospholipase, hyaluronidase and antigens, all of which cause different clinical manifestations (1, 5). Upon being stung, the spectrum of manifestations ranges from nonspecific skin lesions to anaphylactic shock, usually occurring in a previously sensitized person. A toxin-naive person can have cellular damage due to systemic envenomation following multiple stings. Toxemia can lead to rhabdomyolysis, hemolysis, thrombolysis, disseminated intravascular coagulation (DIC), acute tubular necrosis (ATN), acute kidney injury (AKI), centrilobular necrosis of the liver, and subendocardial necrosis (2-5). Anaphylaxis is a dreadful complication occurring within the first few hours of a sting. It may be followed by liver injury, coagulation derangements, rhabdomyolysis or hemolysis, all of which peak in one to three days (5). These were also the complications reported in our case, occurring on the first day but without anaphylaxis.

Rhabdomyolysis and ARDS are very rare conditions, caused by the toxic effects of wasp venom without a severe allergic reaction (4, 6, 7). Rhabdomyolysis and similar



**Figure 3.** Biochemical parameters during hospital stay on the second day of admission. (SCr: Serum creatinine, CPK: Creatinine phosphokinase)

conditions have been reported worldwide for other hymenoptera stings, such as those inflicted by bees and ants. Mejia Vélez reported on 43 cases of acute renal failure (ARF) due to multiple stings of the Africanized bee, and showed that ARF occurs as a result of rhabdomyolysis (6). In addition, Vikran S. and Parashar A. reported on 35 cases of AKI that developed after multiple wasp and bee stings in India; they also demonstrated that AKI developed after rhabdomyolysis (62.3%) (4). Among the study population, the main clinical features at presentation were oliguria (83%) and hematuria (57%). These were also the main symptoms reported in our case.

According to both reports, the developing mechanism of rhabdomyolysis has not been completely clarified. It is thought that direct toxic effect of the venom on muscular tissue plays a role. The causes of renal insufficiency are pigment nephropathy (caused by rhabdomyolysis) and intravascular hemolysis or ATN (developed by the hypotension and acute interstitial nephritis that is thought to be the consequence of the direct effect of the venom) (4). Histamine-like active amines, serotonin, quinines, phospholipase A2, hyaluronidase, melittin, and apamin are responsible for the toxic effects of the venom (8, 9). They have hemolytic, neurotoxic and vasoactive characteristics that may cause intravascular hemolysis and rhabdomyolysis (4, 6, 10).

Therefore, in serious clinical conditions, antihistamines and steroids have beneficial effects. Optimal hydration and alkaline diuresis decrease the ischemic ATN and pigment nephropathy (4, 6, 10-13). In our case, having determined rhabdomyolysis, we protected the renal functions by

Administering NaHCO<sub>3</sub> and appropriate fluid infusion until the serum CPK levels decreased.

Another interesting clinical condition in our case is ARDS, which occurred on the second day of the injury. However, there are few reported instances of ARDS following wasp stings. Arisoy et al. published a case of ARDS developing after a wasp sting (3). The patient concerned initially had no complaints other than dyspnea, but respiratory distress developed approximately 30 min after the sting, and a diagnosis of ARDS was made in the emergency room. The patient was therefore transferred to the ICU, where he completely recovered after appropriate medical and ventilation treatment.

In addition, Sharmila R. et al. reported the death of a 12-year-old Indian boy who developed multiple organ dysfunction syndrome (MODS), evidenced by ARDS, ARF, hepatic dysfunction and hemolysis, after a single wasp sting (14). They also reported that the exact mechanism was not clear, but postulated that a massive release of inflammatory mediators and the activation of a complement cascade may have been responsible, leading to systemic reactions caused by toxin-mediated cellular injuries. Having determined ARDS in our case, we supported the respiratory functions through lung-protective mechanical ventilation and administration of analgesics and sedative infusions until arterial blood gas values and chest radiography improved.

Other than having a local reaction to wasp stings, our patient showed evidence of rhabdomyolysis and ARDS. In a review of cases of multiple wasp stings, MODS, including rhabdomyolysis and ARDS, was reported in only one case (14). Unfortunately, despite best efforts, the patient could not

be salvaged. However, the severity of the complications in that case was presumably related to the degree of the multisystem organ injuries. In our presented case, the complications involved only 2 systems. Early recognition, early diagnosis and aggressive treatment helped in achieving a satisfactory recovery of the renal and respiratory functions.

### CONCLUSION

Multiple hymenoptera envenomation is a serious condition. Although bee and wasp stings are common in Thailand, reports of stings with the severe clinical conditions stated previously are scarce. Rare but severe clinical results may occur due to multiple wasp stings; these include, for instance, organ dysfunction, including intravascular hemolysis, rhabdomyolysis, AKI, ARDS and hepatic dysfunction. The clinical information in this case is therefore valuable and significant as a lethal outcome is likely if such presented conditions are treated incorrectly. With wasp stings, clinicians and nurses should be alert to the possibility of rhabdomyolysis in cases with progressive oliguria and hematuria. In addition, clinicians should be alert to the risk of ARDS in cases with tachypnea and desaturation. The early onset of alkaline diuresis for rhabdomyolysis management, and the provision of appropriate medical and mechanical ventilation support for ARDS, are vital in protecting renal and respiratory functions and preventing morbidity and mortality. There is the potential for fatality should the management of wasp stings be delayed or administered insufficiently.

### List of abbreviations

%: percent; FiO<sub>2</sub>: fractional inspired oxygen concentration; IU/L: international unit per liter; mg/dL: milligram per deciliter; /min: per minute; ml/kg/hr: milligram per kilogram per hour; pCO<sub>2</sub>: partial pressure of carbon dioxide; P/F ratio: ratio of arterial oxygen partial pressure to fractional inspired oxygen; pH: potential of hydrogen ion; pO<sub>2</sub>: partial pressure of oxygen; RBCs/HP: red blood cells per high-power field

**Conflict of interest:** None to be declared.

**Funding and Support:** None.

### REFERENCES

1. Ewan PW. Venom allergy. *BMJ* 1998;316:1365–8.
2. Radhakrishnan H. Acute kidney injury and rhabdomyolysis due to multiple wasp stings. *Indian J Crit Care Med* 2014;18:470–2.
3. Arisoy A, Demirkiran H, Akdeniz H, Ekin S. Adult respiratory distress syndrome after a wasp sting. *Respir Case Rep* 2016;5:165–8.
4. Vikrant S, Parashar A. Acute kidney injury due to multiple hymenoptera stings—a clinicopathological study. *Clin Kidney J* 2017;10:532–8.
5. Dhakal AK, Basnet NB, Shrestha D. Acute kidney injury due to multiple wasp stings in an eight year-old child. *J Kathmandu Med College* 2013;2:145–7.
6. Mejia Ve'lez G. Acute renal failure due to multiple stings by Africanized bees. Report on 43 cases. *Nefrologia* 2010;30:531–8.
7. Pramanik S, Banerjee S. Wasp stings with multisystem dysfunction. *India Pediatrics* 2007;44:788–90.
8. Fitzgerald KT, Flood AA. Hymenoptera stings. *Clin Tech Small Anim Pract* 2006;21:194–204.
9. Thiruventhiran T, Goh BL, Leong CL, Cheah PL, Looi LM, Tan SY. Acute renal failure following multiple wasp stings. *Nephrol Dial Transplant* 1999;14:214–217.
10. Dhanapriya J, Dineshkumar T, Sakthirajan R, Shankar P, Gopalakrishnan N, Balasubramanian T. Wasp sting-induced acute kidney injury. *Clin Kidney J* 2016;9:201–4.
11. Ito K, Imafuku S, Nakayama J. Rhabdomyolysis due to multiple wasp stings. *Case Rep Dermatol Med* 2012;2012:486724.
12. Chowdhury FR, Bari MS, Shafi AM, Ruhan AM, Hossain ME, Chowdhury S, et al. Acute kidney injury following rhabdomyolysis due to multiple wasp stings (*Vespa affinis*). *Asia Pac J Med Toxicol* 2014;3:41–3.
13. Akdur O, Can S, Afacan G. Rhabdomyolysis secondary to bee sting. *Case Rep Emerg Med* 2013;2013:258421.
14. Sharmila RR, Chetan G, Narayanan P, Srinivasan S. Multiple organ dysfunction syndrome following single wasp sting. *India J Pediatric* 2007;74:1111–2.