

Prevalence of Fungal Keratitis (FK) in Patients with Corneal Ulcers in Farabi Eye Hospital, Tehran, 2011-2013

ALIREZA EBADOLLAHI-NATANZI^{1,2,*}, GHOLAMREZA ARAB-RAHMATIPOUR³, SEYED ALI TABATABAEI⁴

¹ Assistant Professor of Toxicology & Pharmacology, Medicinal plants Department, Imam Khomeini Higher Education Center, Agricultural Research, Education and Extension Organization (AREEO), Karaj, Iran

² Institute of Technical and Vocational Higher Education, Agriculture Jihad, AREEO, Tehran, Iran.

³ Laboratory Sciences Expert, Farabi Hospital Laboratory, Medical Sciences of Tehran University, Tehran, Iran

⁴ Associate Professor of Ophthalmology, Emergency Ward, Farabi Hospital, Medical Sciences of Tehran University, Tehran, Iran

Abstract

Background: The fungi include microorganisms which are inhabitant in our environment and sometimes their produced poisons can result in Keratitis and if this disease is not treated appropriately, then blindness will occur. In the present study, the most infectious fungal agents which caused corneal ulcer in patients who referred to Farabi Eye Hospital of Tehran University of Medical Sciences have been identified.

Methods: The sample was taken by ophthalmologist and then analyzed for identification of any fungal pathogen in accordance with laboratory standards.

Results: Most fungi obtained from these samples were related to the genera *Fusarium* (n=60, 49.59±2.96%), *Aspergillus* (n=32, 26.44±2.52%), *Candida albicans* (n=17, 14.05±2.32%) and other fungi (n=12, 9.92±3.16%), respectively. Fungal Keratitis (FK) was observed mostly in men (n=96, 79.34±0.52%). Whilst for women, FK rate was found to be (n= 25, 20.66±0.52%). Our results showed that in farmers and constructional workers, due to trauma there was seen an increased number of FK which resulted from hitting the plant organs and objects in eyes.

Conclusion: It can be concluded that after corneal damage by these fungal agents, toxic metabolite is emerged and finally the human eye will be hurt.

Keywords: Fungal Keratitis; *Fusarium*; *Aspergillus*; Laboratory Diagnosis

How to cite this article: Ebadollahi-Natanzi A, Arab-Rahmatipour G, Tabatabaei SA. Prevalence of Fungal Keratitis (FK) in Patients with Corneal Ulcers in Farabi Eye Hospital, Tehran, 2011-2013. *Asia Pac J Med Toxicol* 2016;5:94-7.

INTRODUCTION

Cornea is the out layer of eye and contrary to other tissues of human body, it lacks blood vessels and this is the reason why cornea is more vulnerable to damage compared with other tissues. There are some risk factors in corneal diseases. They include trauma caused infections which usually occur due to plant stumps in eye, chronic diseases related to outer layers of eye, immunity deficiency and in some rare cases the use of contact lenses (4).

Nowadays, our information about infectious microorganisms and the poisons produced by these microbial agents has been increasingly grown. Fungal species are significant in human life and they would be able to produce toxic metabolites resulting in damage in animal and human tissues.

Mycotoxins are known as fungal secondary metabolites which have toxic effects on human and animals. These toxic effects are dependent on toxicity and exposure levels, age and other factors involved in toxicity severity. Therefore, considering the public health and careful controlling of food materials are so necessary and of importance for human's

health (1). Some fungi such as *Aspergillus* genus include useful species that can be used in food industries (2). Whilst the other species of this genus may result in crop contamination and also they are able to make poisoning for living things and/or to cause carcinogenicity in human (3).

There are few available reports in literatures referring to a series of eye diseases in human and animals which can be formed by fungal, bacterial and viral produced enzyme metabolites (4,5). One of the high importance diseases resulted from fungi is Keratitis. The Keratitis is known as corneal inflammation diseases and may become an infectious disease through microorganisms which is sometimes followed by blindness in human and animals (6-8).

Since the type of treatment in this disease is very crucial and dependent upon laboratory diagnosis, the laboratory methods are of high importance for finding the best and appropriated approach of treatment. In this direction, if the sample is taken more carefully, the more proper initial diagnosis will be resulted. Carefully prepared of direct smears and staining smears along with conventional, appropriated culture media and some diagnostic tests, they would together

*Correspondence to: Alireza Ebadollahi – Natanzi; PhD. Department of Medicinal Plants, Imam Khomeini Higher Education Center, Institute of Technical and Vocational Higher Education, AREEO, Karaj, Iran .

Tel/Fax: +98 2636705003, E-mail: ebad@ihcc.ir

Received 2 May 2016; Accepted 26 August 2016

result in appropriate diagnosis for disease making microorganisms.

The present study is a retrospective study and relating to the patient who referred to Farabi Eye Hospital, Tehran University of Medical Sciences for a two-year period which continued until 2013 due to corneal ulcer and keratitis. The aim of the study was to identify the most important funguses which have great role in fungal keratitis (FK).

METHODS

The information of this study was obtained based on the reports which have been archived in microbiological department of pathobiology laboratory of Farabi Hospital. Looking over the patients' archives, some complementary data were obtained from the accessible files. Most patients were referred from other therapeutical centers placed in other cities.

Specimen: 2180 samples were taken from patients who were affected by Keratitis and referred to Farabi Eye Hospital, Tehran University of Medical Sciences, during approximately two consecutive years. In the carried out research, out of 2180 patients only the patients diagnosed by decisive fungal keratitis (FK) underwent the study. The other probable agents such as bacterial keratitis were not studied and were excluded from the study.

Sampling was taken from surface of cornea by eye specialists and/or eye surgeons who resided in emergency ward of the hospital. Scraping method was used to take samples by means of surgical blades or platinum spatula. The samples were taken using slit lamp microscope from inside deepened and the edge of corneal ulcers of patients whom were gone under local anesthesia. After preparing the lab

slides, they were immediately gone through microscopic analyses. The prepared slides were gram stained for direct smear test. The samples were cultured in laboratory media including Blood Agar (BA), Chocolate Agar (CHOC) and Sabouraud Dextrose Agar (SDA) for identification of any bacterial and fungal pathogens. KOH wet mount is also used for identifying the fungi. The whole tests were done in accordance with laboratory standards. The media were incubated for a period of 24 to 72 hours at an appropriate temperature. Finally, the infectious pathogens causing keratitis were separated and identified. Microscopic experiments and direct smear, wet mount with KOH 10% and the gram staining were all done by lab experts and directed by lab specialists and microbiologists as well.

RESULTS

The result of identified funguses causing FK

In this study, 121 samples (5.55%) were isolated by fungal infections. Most fungi obtained from these samples were related to the genera *Fusarium* (n=60, 49.59±2.96%), *Aspergillus* (n=32, 26.44±2.52%) and *Candida albicans* (n=17, 14.05±2.32%). There were seen few other fungi (n=12, 9.92±3.16%), respectively (Table 1).

The result of this study also showed the highest FK rate was related to *Fusarium* sp (51.56%) which was followed by *Aspergillus* sp (28.13%) in the year 2012. However, due to *Candida albicans*, FK rate was found to be 12.50% (Figure 1).

The results of FK incidence in male and female patients

Fungal Keratitis (FK) was observed (n=96, 79.34±0.52%) in men and (n=25, 20.66±0.52%) in women, respectively (Figure 2).




Figure 1. FK rate caused by different fungal pathogens in the year 2012. 1 (*Fusarium* sp); 2 (*Aspergillus* sp); 3 (*Candida albicans*); 4 (Other fungi)

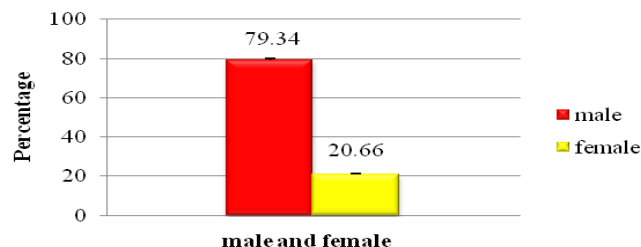


Figure 2. The percentage of FK observed in male and female patients

Table 1. Most fungi isolated from patients affected by FK within two years

Fungi (n=121)	Number	Percentage
<i>Fusarium</i> sp	60	49.59±2.96%
<i>Aspergillus</i> sp	32	26.44±2.52%
<i>Candida albicans</i>	17	14.05±2.32%
*Other Fungi	12	9.92±3.16%

*Other Fungi included: *Alternaria* sp, *Sterile mycelium*, *Penicillium* sp, *Paecilomyces* sp, *Colletotrichum* sp, *Pseudallescheria boydii*, *Curvularia lunata* and *Rhizopus* sp

The results obtained from smear test

The results of this study showed that in severe infections resulted from FK, fungal mycelium was easily seen in direct smear test (Figure 3A-B). This initial report helps physicians to speed up the treatment protocol.

The results obtained from culture media

After 24–72 hrs passed from taking the samples, the grown fungal colonies presented in the media were identified (Figure 4A-B).

DISCUSSION

Funguses are generally considered as damaging agents in agricultural and medical sections throughout the world. These agents are able to create toxic metabolites which cause a series of infectious diseases and consequently sometimes resulting in death (9). Some diseases such as Allergic alveolitis, bronchial asthma and atopic conjunctivitis can be created by fungal micro particles being spread in our environment and these particles may contain special species of Fusarium genus and through making toxic metabolite the abovementioned diseases will be emerged (10,11). Some diseases making funguses such as Fusarium and Aspergillus genera are part of environmental habitants and they are reported in some countries such as India, China, some areas limited to the U.S., France, Hong Kong and Singapore to cause FK (12-17). Generally, saprophytic fungi including

Aspergillus, Fusarium and yeast like microorganisms such as *Candida albicans* are mostly considered as the highest incidence of FK (18,19). In this study, we showed that, both *Fusarium* and *Aspergillus* are the most FK causative for patients referred to Farabi Eye Hospital (Figure 1). However, among these two fungi, the incidence rate of FK caused by *Fusarium* was much higher (Table 1). The continuation of our study also showed FK incidence rate in males was higher (79.34%) when compared to females' (20.66%) (Figure 2). The reason of high incidence rate of FK in males might be searched in a series of parameters including immunological systems differences, vocational parameters, and also the geographical area of their living. In this direction, it should be said that because of more working in exposed areas of farm, men workers are expected to be subject to plant based trauma and accordingly corneal deepened ulcers will be resulted.

In individuals who have compromised immunological systems, there is every likelihood of fungal infection caused by trauma and/or formed by corneal ulcers (20). The corneal ulcers which can be formed by fungal metabolism are mostly seen among the farmers in countryside areas and also observed in structural and unroofed places' workers. In this regard, it should be said that fungal microorganisms would be able to become pathogenesis after the cornea damaged by a trauma which can occur through hitting external objects

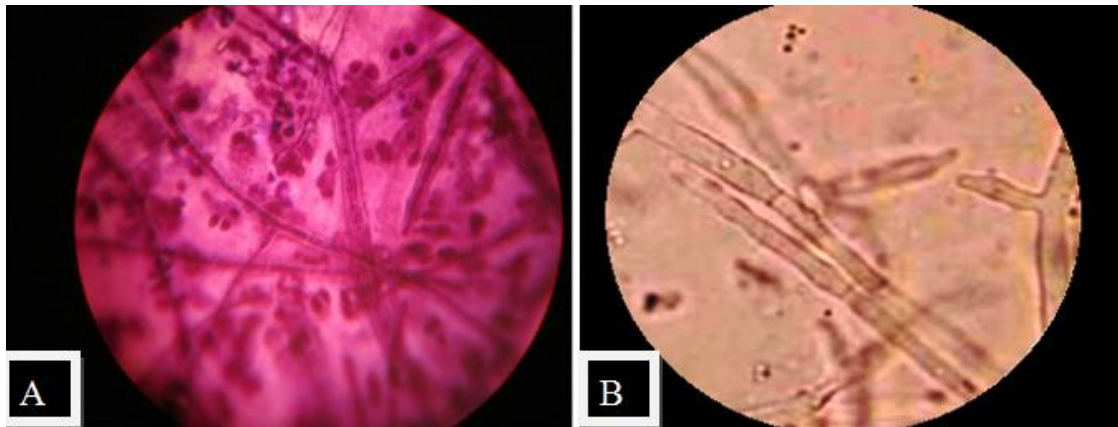


Figure 3. Representing gram stain of corneal smear to reveal hyphae (A) and KOH wet mount-fungal filaments (B) in FK

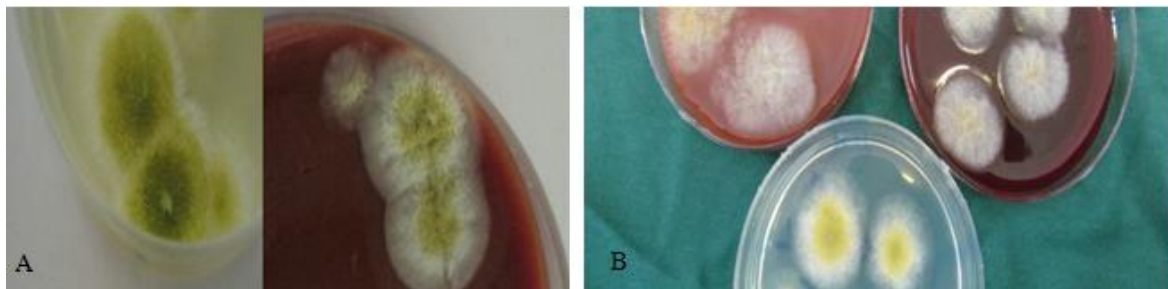


Figure 4. Illustrating *Aspergillus* sp (A) and *Fusarium* sp (B) colonies in laboratory culture media resulted from FK

facing eyes with plants and dusts base (4,21). Since FK treatment is sometimes difficult and might be unresponsive to ocular drugs, it leads to severe damaging in cornea and blindness may even be ensued (22,23).

Most symptoms of FK include ocular redness, pain, feeling external objects in eyes and tearing. These symptoms cannot merely bear a certain and confident diagnosis on FK. Accordingly, laboratory reports would be of high importance for an appropriate diagnosis to take place which would be followed by accurate and proper treatment.

In this study, some routine methods such as gram stained direct smears relating to the cornea and also KOH wet mount were used for early diagnosis of FK (Figure 3A-B). In fact, the results of this diagnostic laboratory approaches lead physicians to speed up any necessary procedures for FK treatment. This approach together with the results obtained from culture media incubated within 24 to 72 hours certainly result in comprehensive treatment.

LIMITATIONS

In recent years, the use of other diagnostic methods such as molecular approaches has been growing for detection of pathogens. The high costs of reagents needed for considering this kind of methods was one of the limitations that caused them not to be applied to this research. There was seen incomplete information on primary treatments on patients referred from other therapeutic centers.

CONCLUSION

Although the incidence of these diseases has been fallen down, the studies show that FK due to population increasing, the elevated use of contact lens, is increasingly to grow. Based on our data, the most dominant fungal keratitis was related to *Fusarium* and *Aspergillus* genera, respectively.

ACKNOWLEDGEMENT

The authors are obliged to appreciate all laboratory personnel of Pathobiology located in Farabi Hospital.

REFERENCES

- Karlovsky P. Biological detoxification of the mycotoxin deoxynivalenol and its use in genetically engineered crops and feed additives. *Appl Microbiol Biotechnol* 2011; 91: 491–504.
- Balali GR, Minaefar A, Sharifnabi B. Zymography variation of pectinase in *Aspergillus niger* and *Aspergillus flavus*. *Iran J Biol* 2007; 20:5-14.
- Ghazani MH. Aflatoxin M1 contamination in pasteurized milk in Tabriz (northwest of Iran). *Food Chem Toxicol* 2009; 47:1624-5.
- Mravičić I, Dekaris I, Gabrić N, Romac I, Glavota V, Mlinarić-Sviben M. Trichophyton Spp. fungal keratitis in 22 years old female contact lenses wearer. *Coll Antropol* 2010; 34: 271–4.
- Ledbetter EC, Patten VH, Scarlett JM, Vermeylen FM. In vitro susceptibility patterns of fungi associated with keratomycosis in horses of the northeastern United States: 68 cases (1987-2006). *J Am Vet Med Assoc* 2007; 231: 1086-91.
- Srinivasan M. Fungal keratitis. *Curr Opin ophthalmol* 2004; 15:321-7.
- Gelatt KN. Essentials of Veterinary Ophthalmology: Canine Corneal: Diseases and Surgery. 2nd ed. United States: Wiley-Blackwell Pub; 2008.
- Whitcher JP, Srinivasan M, Upadhyay MP. Corneal blindness: A global perspective. *Bull World Health Organ* 2001; 79:214–21.
- De Lucca AJ. Harmful fungi in both agriculture and medicine. *Rev Iberoam Micol* 2007; 24: 3-13.
- Anaissie EJ, Kuchar RT, Rex JH, Francesconi A, Kasai M, Müller FM et al. Fusariosis associated with pathogenic *Fusarium* species colonization of a hospital water system: a new paradigm for the epidemiology of opportunistic mold infections. *Clin Infect Dis* 2001; 33:1871-8.
- Krysinska-Traczyk E, Kiecana I, Perkowski J, Dutiewicz J. Levels of fungi and mycotoxins in samples of grain and grain dust collected on farms in Eastern Poland. *Ann Agric Environ Med* 2001; 8: 269-74.
- Bharathi MJ, Ramakrishnan R, Meenakshi R, Padmavathy S, Shivakumar C, Srinivasan M. Microbial keratitis in South India: influence of risk factors, climate, and geographical variation. *Ophthalmic Epidemiol* 2007; 14:61–9.
- Xie L, Zhong W, Shi W, Sun S. Spectrum of fungal keratitis in north China. *Ophthalmology* 2006; 113:1943–8.
- Alfonso EC, Cantu-Dibildox J, Munir WM, Miller D, O'Brien TP, Karp CL et al. Insurgence of *Fusarium* keratitis associated with contact lens wear. *Arch Ophthalmol* 2006; 124:941–7.
- Khor WB, Aung T, Saw SM, Wong TY, Tambyah PA, Tan AL et al. An outbreak of *Fusarium* keratitis associated with contact lens wear in Singapore. *JAMA* 2006; 295: 2867–73.
- Gaujoux T, Chatel MA, Chaumeil C, Laroche L, Borderie VM. Outbreak of contact lens-related *Fusarium* keratitis in France. *Cornea* 2008; 27:1018–21.
- Ma SK, So K, Chung PH, Tsang HF, Chuang SK. A multi-country outbreak of fungal keratitis associated with a brand of contact lens solution: the Hong Kong experience. *Int J Infect Dis* 2009; 13:443–8.
- Thomas PA, Kalliamurthy J. Mycotic keratitis: epidemiology, diagnosis and management. *Clin Microbiol Infect* 2013; 19:210–20.
- Ebadollahinatanzi A, Arabrahmatipour G, Tabatabaei SA. Identification of the most common pathogens formed by environmental fungus toxins in human's eye. *Toxicol Lett* 2014; 229: S132-3.
- Balloy V, Huerre M, Latgé JP, Chignard M. Differences in patterns of infection and inflammation for corticosteroid treatment and chemotherapy in experimental invasive pulmonary aspergillosis. *Infect Immun* 2005; 73: 494-503.
- Bindu N. Fungal Keratitis. *Kerala J Ophthalmol* 2008; 20:169-73.
- Richardson MD, Warnock DW. Fungal infection: diagnosis and management, 4th ed. England; Wiley-Blackwell: 2012.
- Dóczi I, Gyetvai T, Kredics L, Nagy E. Involvement of *Fusarium* spp. in fungal keratitis. *Clin Microbiol Infect* 2004; 10: 773-6.