

## CASE REPORT

# 2, 4-D Dichlorophenoxyacetic Acid Poisoning; Case Report and Literature Review

SUJATA HIRAN<sup>1,\*</sup>, SUNIL KUMAR<sup>2</sup><sup>1</sup>Director and Head, Department of Medicine, J.L.N. Hospital and Research Centre, Bhilai, India<sup>2</sup>Senior Medical Officer, Department of Medicine, J.L.N. Hospital and Research Centre, Bhilai, India

## Abstract

**Background:** 2, 4-dichlorophenoxyacetic acid, (2, 4-D) is a selective herbicide available as the acids, esters and several salts which vary in their chemical properties, environmental behaviour, and to a lesser extent toxicity. The salt and ester forms are derivatives of the parent acid. It is widely used as a weed killer. The 2, 4-D dimethylamine is one of the salts of this group.

**Case Presentation:** We report a case of ingestion of 2, 4-D herbicide intentionally. The patient had presented in a local hospital but transferred to our hospital in a state of deep coma. CT scan head showed diffuse cerebral oedema. The patient recovered completely after treatment with forced alkaline diuresis.

**Discussion:** Anticholinesterase compounds are the most commonly used insecticide and the commonest compound used as poison in India. This case report emphasizes that not all poisonings are caused by anticholinesterase compounds. The initial clinical manifestations of 2, 4-dichlorophenoxyacetic acid (2, 4-D) poisoning are very similar to alcohol, sedative drugs, or aromatic chlorinated hydrocarbons making it even more difficult for the treating physician to suspect poisoning due to these compounds. It is thus important to identify the correct compound for proper management. Prompt diagnosis and correct treatment can save the life of a patient. The poisoning is also sometimes confused with poisoning due to anticholinesterase compound.

**Conclusion:** 2, 4-D is a poison which carries a high mortality. Prolonged coma, metabolic complications, skeletal muscle injury and myotonia are some of the complications of 2, 4-D. Forced alkaline diuresis resulted in saving our patient which otherwise had poor prognosis.

**Keywords:** Alkaline Diuresis; 2,4-Dichlorophenoxyacetic Acid; Herbicide

**How to cite this article:** Hiran S, Kumar S. 2, 4-D Dichlorophenoxyacetic Acid Poisoning; Case Report and Literature Review. *Asia Pac J Med Toxicol* 2017;6:29-33.

## INTRODUCTION

Chlorophenoxy herbicides poisoning is uncommon. It is used widely for the control of broad-leaved weeds. These compounds exhibit a variety of mechanisms of toxicity which includes dose-dependent cell membrane damage, uncoupling of oxidative phosphorylation, and disruption of acetyl-coenzyme A metabolism (1). 2, 4-D is a Chlorophenoxy herbicide which has no antidote (2).

Forced alkaline diuresis is the treatment of choice and if timely instituted may improve the otherwise very poor prognosis in severe intoxication with 2, 4-D and related weed killers. The goal of this study is to emphasize the role of accurate diagnosis and the management of 2, 4-D herbicide poisoning.

## CASE PRESENTATION

A 33-year-old female gave history of ingesting 70 ml liquid containing 58% of 2, 4-D dimethylamine salt. Prior to coming to our hospital, she was admitted to a local hospital with the complaints of vomiting and altered sensorium in

form of drowsiness. She was given symptomatic treatment as gastric lavage and IV fluids with sodium bicarbonate. However, patient's sensorium deteriorated and she became unconscious after 48 hours of admission. She remained in this state for 2 days in the local hospital. She was then transferred to our hospital 4-5 days after the intake of the poison.

On admission, she was in GCS, E<sub>1</sub>M<sub>1</sub>V<sub>1</sub>. Pulse was 100/min and B.P 110/90 mm of Hg and Respiratory rate of 16/min. Her pupils were small in size but reactive. Muscle tone was decreased and tendon reflexes were absent. The chest was clear. The ECG showed sinus tachycardia and marked T inversion in chest leads (Figure 1). An urgent CT scan showed features of diffuse cerebral edema (Figure 2) and acid blood gas analysis showed mild metabolic acidosis. There was biochemical evidence of severe muscle injury. The creatinine phosphokinase (CPK) level went up to maximum 21910 IU and remained high for several days. LDH, AST, and ALT levels also rose but bilirubin and alkaline phosphatase remained normal. Laboratory values are shown in chronological order in Table 1.

\*Correspondence to: Sujata Hiran; MD, Director and HOD, Department of Medicine, J.L.N. Hospital and Research Centre, Bhilai, India.  
Tel: +91 940 798 35 01, Fax: +91 788 224 19 26, Email: sujatahiran@gmail.com  
Received 28 January 2017, Accepted 15 March 2017

The patient was started on supportive management with urinary alkaline diuresis. Alkaline diuresis was initiated by giving 1Meq /kg of sodium bicarbonate as IV bolus and then adding 80 Meq of sodium bicarbonate with 20Meq of potassium in one liter of 5% dextrose saline and infusing it at the rate to keep urinary pH- 8.0 and to maintain urine output

at 6ml/min. Dexamethasone was given to combat cerebral edema. The patient started responding to the above treatment and within 12-14 hours after initiation of treatment, patient's GCS improved to E<sub>3</sub>M<sub>5</sub>V<sub>2</sub>. The tendon reflexes became brisk and the muscle weakness improved. She became fully conscious after 48 h of treatment and started accepting oral feeds. Her ECG reverted to normal. Her biochemical parameters started falling and the MRI (Figure 3) done 3 days after CT scan head revealed disappearance of cerebral edema. She was discharged after seven days of admission in a stable condition. Follow-up after 2 weeks of discharge revealed normal biochemical parameters and she was in good physical condition.

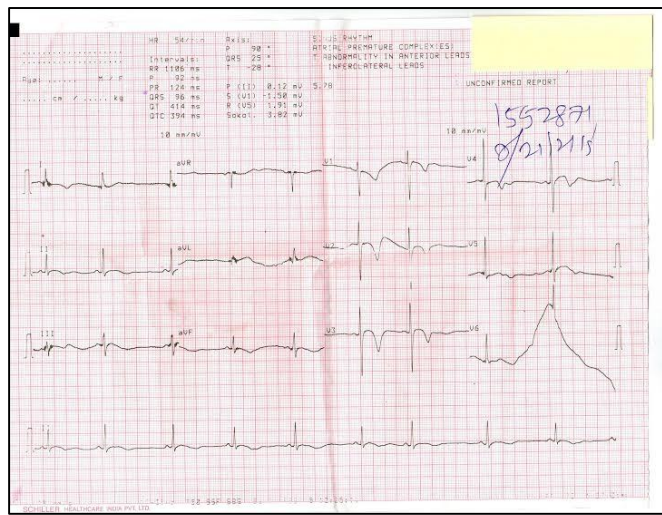


Figure 1. ECG showing marked T wave inversion

## DISCUSSION

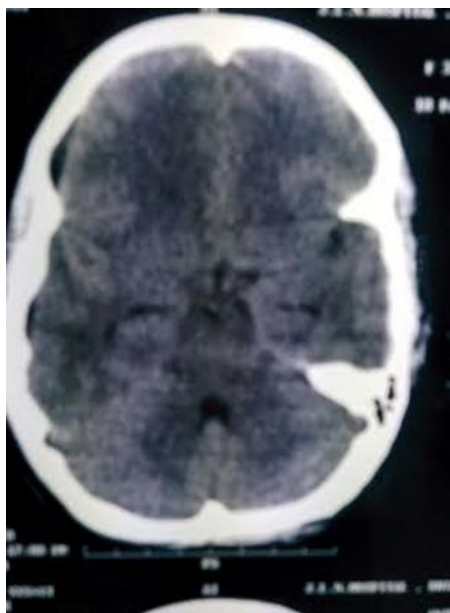Anticholinesterase compounds are the most common method of poisoning in India but herbicide poisoning is also a method of suicide and is associated with high morbidity and mortality (3). Among different herbicidal poisonings, the most predominantly found poisonings are paraquat and glyphosate (4). The incidence of 2, 4-dichlorophenoxy acetic acid poisoning is scanty and only few cases are reported from India (5).

2, 4-dichlorophenoxy acetic acid commonly known as 2, 4-D is a plant herbicide and secondarily a plant growth regulator (6). It was developed in the 1940s and is the most commonly used pesticide in the non-agricultural sector and one of the top ten most commonly used in the agricultural

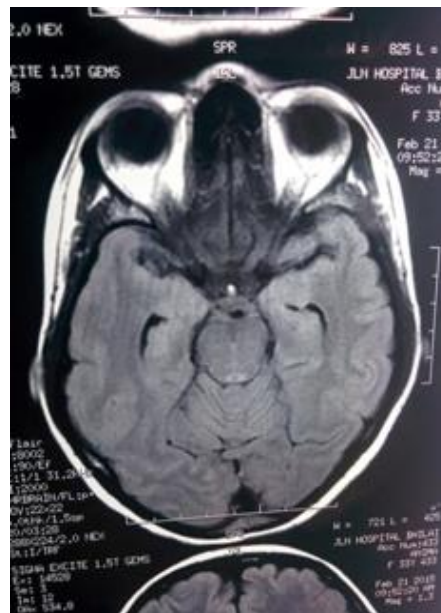
Table 1. Clinical laboratory findings

Laboratory Values	Days after admission to the ward									
	1	2	3	4	5	6	7	8	9	10
Urea mg/dL	43	27	47	ND*****	ND	34	ND	ND	ND	ND
Creatinine mg/dL	1	1	1.1	ND	ND	1	ND	0.8	ND	0.7
Na mmol/L	138	144	143	ND	147	143	ND	138	138	143
K mmol/L	3.6	3.7	3.6	ND	4.9	4.8	ND	4.2	4.1	4.3
CPK I.U/L*	17480	21910	20178	1368	15086	5786	3874	1938	932	46
CKMB in I.U	151	214	191	159	150	80	56	36	34	8
LDH U/L	1353	2308	2124	1974	1608	1429	1296	1269	800	518
Total Bilirubin mg/dL	0.2	0.5	0.4	ND	0.4	0.4	ND	ND	ND	ND
AST I.U/L **	ND	486	461	ND	378	251	186	130	86	ND
ALT I.U/L ***	58	115	148	ND	158	137	121	104	70	25
ALP I.U/L****	ND	89 L	ND	ND	98 L	87 L	ND	ND	ND	ND
Calcium mg/dL	ND	7.4	9.3	ND	9.3	8.8	ND	ND	ND	ND
Phosphorus mg/dL	ND	1.8	2.7	ND	1.2	1.7 L	ND	ND	ND	ND
D.Bilirubin mg/dL	ND	0.2	0.2	ND	0.2	0.4	ND	ND	ND	ND
I.Bilirubin mg/dl	ND	0.3	0.2	ND	0.2	0.1	ND	ND	ND	ND
ECG	Abnormal	Abnormal	Normal	Normal	ND	ND	ND	ND	ND	ND

\* Creatinine phosphokinase  
\*\* Aspartate aminotransferase  
\*\*\* Alanine aminotransferase  
\*\*\*\* Alkaline phosphatase  
\*\*\*\*\* Tests Not Done



**Figure 2.** CT scan head shows diffuse cerebral edema



**Figure 3.** MRI head shows disappearance of cerebral edema

sector (7). It was the first widely used herbicide to control broadleaf plants, and it has significantly contributed to modern weed control in agriculture. It was one of the two ingredients in infamously known as Agent Orange, the other being 2, 4, 5-trichlorophenoxyacetic acid (2, 4, 5-T) - a dangerous mixture used by the military to defoliate the Vietnam's forest in the Vietnam War (8). At that time, the most visible detrimental effects on human health were caused by dioxin, which is a highly toxic byproduct (9).

2, 4-D is chemically classified as a Chlorophenoxy herbicide and is an odorless crystalline powder that is colorless or white to yellow (10). In addition to 2, 4-D itself, there are eight salts and esters of 2, 4-D of which 2, 4-D dimethylamine salt (DMA) and 2 ethylhexyl ester (EHE) form accounts for approximately 90-95% of the total global use. In humans, 2, 4-D exposure can occur through inhalation, skin absorption, ingestion, and skin/eye contact. The steady increase of applications for genetically engineered plants causing resistance to Glyphosate and Paraquat resulted in widespread use of 2, 4-D. It is difficult to develop resistance to 2, 4-D (11).

These herbicides are easily available and in spite of their widespread use, they are not commonly encountered poisons. Acute poisoning with these compounds is uncommon and in most cases outcome was fatal (12). Case reports and observational studies provide the majority of information regarding the toxicological effects of 2, 4-D in incidents involving human poisonings (1, 13, 21). Researchers compiled the medical cases of 69 people from 1962 to 2004 who had ingested 2, 4-D and other Chlorophenoxy herbicides and reported death in 23 patients (1).

Its toxic effects involve heart, central and peripheral nervous system, liver, kidneys, muscles, lungs and endocrine system (2). The described symptoms of intoxication include

nausea, vomiting, abdominal pain, hepatic injury and kidney injury, hypertonia, areflexia, depression of central nervous system, fasciculations, coma, hypotension, and ECG changes (13).

The toxicity associated with ingestion whether by accidental or suicidal intent is not only complicated by the high concentration of active ingredient but also by the stabilizers, emulsifiers and solvents (14). Many of the reported cases are not clear-cut cases of 2, 4-D exposure but involve other chemicals (15). According to the data collected by U.S. Environmental Protection Agency, some 2, 4-D is contaminated with 2,3,7,8-TCDD, a potent dioxin (15).

The acute effects on the central nervous system are impaired coordination, unconsciousness and coma. Peripheral neuromuscular effects including muscle twitching, weakness, and loss of tendon reflexes have been reported (1). 2,4-D exposure causes neurotoxic effects, including disruption of cell membrane transportation, and alterations to the blood-brain barrier mechanism (13, 16). It is therefore possible that lethal doses of Chlorophenoxy compounds may cause structural as well as functional damage to the brain. In human observations, many exposed to 2,4-D have exhibited degeneration of the central nervous system, decreased nerve conduction, delayed muscle contraction, as well as suicidal thoughts, depression, anxiety, aggression and post-traumatic stress syndrome (17).

Controversy and lack of controlled clinical studies exist surrounding the most effective way to induce clearance of 2,4-D. Urine alkalinisation is one form of enhance elimination that may be useful in some poisoning such as phenobarbital, chlorpropamide, salicylate and chlorophenoxy herbicides especially 2, 4-D and mecoprop, although their mechanisms are not clear (1, 18).

Oghabian ZI et al (19). treated a case of intentional



poisoning of 2, 4-D causing liver damage and rhabdomyolysis with sodium bicarbonate and other conservative measures and the patient was discharged from the hospital 5 days after admission in good condition and normal laboratory test. Two case reports resulting into death were reported by Iken et al (20).

Demographic studies conducted in a tertiary care hospital of India found Paraquat and Glyphosate as the common herbicides used as poison (11). Reports of 2, 4-D poisoning cases are rare and a total of 16 cases are reported from India of which only 4 survived.

This is the second case report from India of 2, 4 -D, salt poisoning with severe muscle injury and cerebral oedema treated successfully by alkaline diuresis and symptomatic treatment with full recovery. A similar case has been reported by Anudhkar et al (21), where the patient was semiconscious and hyporeflexic with signs of raised intracranial tension. Their patient also improved after proper treatment in the form of diuresis and other symptomatic care.

Five of the six cases reported from North India have had a fatal outcome within the hospital. The lone survivor was a 31-year-old lady who had a prolonged hospital course before recovery (5). A recent case report published in 2015 by Vaneet Jearth et al reported a rare survival after 2,4-D (ethyl ester) poisoning treated by forced alkaline diuresis (12). The other case reports from India have reported fatality due to this poison (3, 22, 23).

In our patient, muscle damage and cerebral oedema were the major manifestations with striking elevation of CPK, LDH and AST. The altered sensorium occurring late was due to cerebral oedema. The generalized T wave changes suggested myocardial injury. Myopathic symptoms including limb muscle weakness, loss of tendon reflexes, and increased creatinine-kinase activity have also been observed in our patient.

Chlorophenoxy herbicides are weak acids ( $pK_a=2.6$  for 2, 4-D), and excreted in the urine unchanged. Alkaline diuresis especially in severe 2, 4-D poisoning may be lifesaving. The treatment is to accelerate excretion of 2, 4-D and to limit the concentration of toxins in the kidney. A urine flow of 4-6ml/min is desirable.

Hypokalemia may occur during alkaline diuresis which can be corrected by giving 20-40mEq of potassium supplements in one litre of fluid (24). Myotonia may also occur in acute 2, 4-D poisoning thus diuretics should be avoided (19). Consider hemodialysis in severe cases, particularly where excess fluid administration is not advised (2). Hemodialysis has been used as an effective method to treat severe cases of 2, 4-D poisoning with coma (25).

Alkalinizing the urine by including sodium bicarbonate (44-88 mEq per liter) in the intravenous solution accelerates excretion of 2,4-D substantially, because the weak acid is in an ionized state in the renal tubule and thus cannot diffuse from the tubule into the blood. Renal clearance is minimal at an acidic pH of 5.1 (0.14 mL/min) compared to clearance at a pH of 8.3 (63 mL/min) (18).

Routine resuscitation, close observation, supportive care, gastrointestinal decontamination, administration of activated charcoal and sorbitol and correction of electrolyte

abnormalities and acidosis should be performed for all patients. There is no specific antidote for phenoxy compounds but sodium bicarbonate may be useful by altering the pharmacokinetics of 2, 4-D (24). In cases of 2, 4-dichlorophenoxyacetic acid poisoning, cerebral oedema should be in mind and an alkaline diuresis can increase herbicide elimination though there is lack of randomized controlled trials of overall effect of urinary alkalization (26).

It is important to suspect herbicide poisoning as prompt diagnosis and treatment can save the life of the patient.

### CONCLUSION

The poison with 2, 4-D is rare and it does not have any antidote. The early recognition and urine alkalization with high flow urine may save the patient. 2, 4-D is a poison which carries a high mortality. Prolonged coma, metabolic complications, skeletal muscle injury and myotonia are some of the complications of 2, 4-D. Forced alkaline diuresis resulted in saving our patient which otherwise had poor prognosis.

**Conflict of interest:** None to be declared.

**Funding and support:** None.

### REFERENCES

1. Bradberry SM, Proudfoot AT, Vale JA. Poisoning Due to Chlorophenoxy Herbicides. *Toxicol Rev* 2004;23:65-73.
2. Bradberry SM, Watt BE, Proudfoot AT, Vale JA. Mechanisms of toxicity, clinical features, and management of acute chlorophenoxy herbicide poisoning: a review. *J Toxicol Clin Toxicol* 2000;38:111-22.
3. Singh S, Yadav S, Sharma N, Malhotra P, Bamberg P. Fatal 2,4 D (ethyl ester) ingestion. *J Assoc Physicians India* 2003;51:609-10.
4. Cherukuri H, Pramoda K, Rohini D, Thunga G, Vijaynarayana K, Sreedharan N et al. Demographics, clinical characteristics and management of herbicide poisoning in tertiary care hospital. *Toxicol Int* 2014;21:209-13.
5. Bhalla A, Suri V, Sharma N, Mahi S, Singh S. 2, 4-D (Ethyl ester) poisoning. Experience at a tertiary care center in Northern India. *Emerg Med J* 2008;25:30-2.
6. Tomlin CDS. The Pesticide Manual: A World Compendium. 14th ed. British Crop Protection Council: United Kingdom; 2006.
7. [No Author]. Pesticides Industry Sales and Usage 2006 and 2007 Market Estimates. United States Environmental Protection Agency: Washington DC. Available at <https://www.epa.gov/pesticides/pesticides-industry-sales-and-usage-2006-and-2007-market-estimates>
8. Bounty A. The effects of Agent orange and its consequences. Global research; 2007. Available from: <http://www.globalresearch.ca/the-effects-of-agent-orange-and-its-consequences/4490>
9. [No Author]. Ingredients Used in Pesticide Products: 2, 4-D". United State Environmental Protection Agency (EPA): United State; 2015. Available from: <https://www.epa.gov/ingredients-used-pesticide-products/24-d>
10. [No Author]. OSHA Occupational Chemical Database. Available from: <http://www.osha.gov/chemicaldata/chemResult.html?RecNo=750>
11. XiaoZhi Lim. Herbicide-resistant crops can exacerbate 'superweeds' but new GM versions can help control problem.

- Genetic Literacy Project: 2014. Available from: <https://www.geneticliteracyproject.org/2014/06/27/herbicide-resistant-crops-can-exacerbate-superweeds-but-new-gm-versions-and-judicious-use-can-control-problem/>
12. Environmental health criteria. 2, 4-dichlorophenoxyacetic acid (2, 4-D29) Geneva: WHO 1984
  13. Jearth V, Negi R, Chauhan V, Sharma K. A rare survival after 2, 4-(ethyl –ester) poisoning: Role of forced alkaline diuresis. *Indian J Crit Care Med* 2015;19:57-8.
  14. Bjorling-Poulsen M, Andersen HR, Grandjean P. Potential developmental neurotoxicity of pesticides used in Europe. *Environ Health* 2008;7:50.
  15. Herbicide Fact Sheet Journal of Pesticide Reform/ Winter. 2005: VOL. 25, NO. 4-updated 4/2006.
  16. Edwards D. Reregistration Eligibility Decision for 2, 4-D. United States Environmental Protection Agency, Office of Prevention, Pesticides and Toxic Substances: Washington DC; 2005.
  17. Bongiovanni B, De Lorenzi P, Ferri A, Konjuh C, Rassetto M, Evangelista de Duffard AM et al. Melatonin decreases the oxidative stress produced by 2, 4- dichlorophenoxyacetic acid in rat cerebral granule cells. *Neurotox Res* 2007;11:93-9.
  18. Garabrant DH, Philbert MA. Review of 2,4-dichlorophenoxyacetic acid (2,4-D) epidemiology and toxicology. *Crit Rev Toxicol* 2002;32:233-57.
  19. Proudfoot AT, Krenzelok EP, Vale JA. Position paper on urine alkalization. *J Toxicol Clin Toxicol* 2004;42:1-26.
  20. Oghabian Z, Ghanbarzadeh N, Sharifi MD, Mehrpour O. Treatment of 2, 4-Dichlorophenoxyacetic Acid (2, 4-D) Poisoning; a Case Study. *Int J Med Toxicol Forensic Med* 2014;4:104-7.
  21. Derkaoui IA, Malkki M, Attari A, Besri S, Amarti A, Khatouf M et al. P50: Fatal poisoning by 2-4 dichlorophenoxyacetic acid: About two cases. *Toxicologie Analytique et Clinique* 2014;26:S50-1.
  22. Aundhakar SC, Mahajan SK, Mhaskar DM, Agarwal ShM. Hypotonia– A rare Complication of 2, 4-D Amine Poisoning. *Indian J Forensic Med Toxicol* 2013;7:171-3.
  23. Nand N, Kumar H. A rare presentation of 2, 4-Dichlorophenoxyacetic acid (2, 4-D) Poisoning). *J Indian Academy Clin Med* 2013;14:171-2.
  24. Parveen D, Vasudev, M. A rare case of 2, 4-Dichlorophenoxyacetic acid (sodium salt) poisoning fatality. *Indian J forensic Med Toxicol* 2011;5:183-4.
  25. Roberts J, Reigart JR. Recognition and management of pesticide poisonings. 6th ed. EPA: Washington DC; 2013.
  26. Moshiri M, Mousavi SR, Etemad L. Management of 2, 4-Dichlorophenoxyacetic Acid Intoxication by Hemodialysis: A Case Report. *Int J Toxicol* 2016;10:53-5.
  27. Roberts DM, Buckley NA. Urinary alkalisation for acute chlorophenoxy herbicide poisoning. *Cochrane Database Syst Rev* 2007;1:CD005488.